

# Endoscopic internal drainage and low negative-pressure endoscopic vacuum therapy for anastomotic leaks after oncologic upper gastrointestinal surgery

## Authors

Carlo Felix Maria Jung<sup>1</sup>, Rachel Hallit<sup>2</sup>, Annegret Müller-Dornieden<sup>3</sup>, Mélanie Calmels<sup>4</sup>, Diane Goere<sup>4</sup>, Ulriikka Chaput<sup>5</sup>, Marine Camus<sup>5</sup>, Jean Michel Gonzalez<sup>6</sup>, Marc Barthet<sup>6</sup>, Jérémie Jacques<sup>7</sup>, Romain Legros<sup>7</sup>, Thierry Barrioz<sup>8</sup>, Fabian Kück<sup>9</sup>, Ali Seif Amir Hosseini<sup>10</sup>, Michael Ghadimi<sup>3</sup>, Steffen Kunsch<sup>1</sup>, Volker Ellenrieder<sup>1</sup>, Edris Wedi<sup>1,11</sup>, Maximilien Barret<sup>2</sup>

## Institutions

- 1 Department of Gastroenterology, Gastrointestinal Oncology and Endocrinology, University Medical Center Göttingen, Göttingen, Germany
- 2 Department of Gastroenterology and Gastrointestinal Oncology, Hôpital Cochin, Assistance Publique-Hôpitaux de Paris and University of Paris, Paris, France
- 3 Department of General, Visceral and Pediatric Surgery, University Medical Center Göttingen, Göttingen, Germany
- 4 Department of Digestive Surgery, Hôpital Saint-Louis, Assistance Publique-Hôpitaux de Paris, University of Paris, Paris, France
- 5 Department of Gastroenterology, Hôpital Saint-Antoine, Assistance Publique-Hôpitaux de Paris and Sorbonne University, Paris, France
- 6 Department of Gastroenterology, Hôpital Nord, Assistance Publique des Hôpitaux de Marseille, Aix-Marseille University, Marseille, France
- 7 Department of Endoscopy and Gastroenterology, Dupuytren University Hospital, Limoges, France
- 8 Department of Gastroenterology, Poitiers University Hospital, Poitiers, France
- 9 Department of Medical Statistics, University Medical Center, University of Göttingen, Göttingen, Germany
- 10 Institute for Diagnostic and Interventional Radiology, University Medical Center Göttingen, Göttingen, Germany
- 11 Department of Gastroenterology, Gastrointestinal Oncology and Interventional Endoscopy, Sana Klinikum Offenbach, Offenbach, Germany

submitted 30.7.2020

accepted after revision 27.1.2021

published online 27.1.2021

## Bibliography

Endoscopy

DOI 10.1055/a-1375-8151

ISSN 0013-726X

© 2021. Thieme. All rights reserved.

Georg Thieme Verlag KG, Rüdigerstraße 14,  
70469 Stuttgart, Germany

 Tables 1 s–3 s

Supplementary material is available under  
<https://doi.org/10.1055/a-1375-8151>

## Corresponding author

Carlo Felix Maria Jung, MD, Department of Gastroenterology, Gastrointestinal Oncology and Endocrinology, University Medical Center Göttingen, Robert-Koch-Str.40, 37075 Göttingen, Germany  
[carlo.jung@gmx.de](mailto:carlo.jung@gmx.de)

## ABSTRACT

**Background** Endoscopic internal drainage (EID) with double-pigtail stents or low negative-pressure endoscopic vacuum therapy (EVT) are treatment options for leakage after upper gastrointestinal oncologic surgery. We aimed to compare the effectiveness of these techniques.

**Methods** Between 2016 and 2019, patients treated with EID in five centers in France and with EVT in Göttingen, Germany were included and retrospectively analyzed using univariate analysis. Pigtail stents were changed every 4 weeks; EVT was repeated every 3–4 days until leak closure.

**Results** 35 EID and 27 EVT patients were included, with a median (interquartile range [IQR]) leak size of 0.75 cm (0.5–1.5). Overall treatment success was 100% (95% confidence interval [CI] 90%–100%) for EID vs. 85.2% (95%CI 66.3%–95.8%) for EVT ( $P=0.03$ ). The median (IQR) number of endoscopic procedures was 2 (2–3) vs. 3 (2–6.5;  $P=0.003$ ) and the median (IQR) treatment duration was 42 days (28–60) vs. 17 days (7.5–28;  $P<0.001$ ), for EID vs. EVT, respectively.

**Conclusion** EID and EVT provide high closure rates for upper gastrointestinal anastomotic leaks. EVT provides a shorter treatment duration, at the cost of a higher number of procedures.

## Introduction

Anastomotic leakage after oncologic upper gastrointestinal (GI) resection occurs in 0–35% of patients after esophagectomy and 0–4.4% after gastrectomy [1–4]. Endoscopic treatment options include self-expandable metal stents (SEMSs), over-the-scope (OTS) clips, endoscopic vacuum therapy (EVT), and endoscopic internal drainage (EID) [5].

EVT applies negative pressure to the wound through a sponge connected to a suction device by a nasogastric tube. Low negative-pressure EVT with  $-20$  to  $-50$  mmHg negative pressure is a variant of EVT with comparable treatment success to conventional EVT [6]. In general, intracavitary standard EVT acts by actively closing the defect and draining the wound secretions. Intraluminal EVT closes the defect and diverts biliary reflux and gastric secretions away from the anastomosis. Applying less negative pressure ( $-20$  to  $-50$  mmHg) provides more diversion of secretions than active wound closure.

EID treatment was introduced for leaks after bariatric surgery [7–9], and has been recently proposed for the management of anastomotic leaks following oncologic upper GI surgery [9]. EID works by passively draining extraluminal secretions towards the GI tract.

Our aim was to compare the effectiveness of EID and EVT for the treatment of leakage after upper GI oncologic surgery.

## Methods

### Inclusion criteria

Between 2016 and 2019, patients with leaks after oncologic upper GI surgery at five university hospitals in France and one center in Germany were included. The study was approved by the Ethics Committees of the University of Göttingen and University of Paris.

All patients in France were treated with EID, whereas patients in Germany received low negative-pressure EVT. Each treatment was considered to be the best possible care according to the interdisciplinary consents at each institution. Patients with esophageal perforations or with initial OTS clip or SEMS placement were excluded. Leak size was measured during the index endoscopy.

Treatment success was defined as the closure of the anastomotic leak, documented at endoscopy, and the absence of a perianastomotic collection on computed tomography. Overall treatment success was defined as the closure of the leak by any endoscopic means. Primary treatment success was defined as the closure of the leak achieved by one type of endoscopic treatment only.

### EID technique

Endoscopies were performed with the patient under general anesthesia and with orotracheal intubation using conventional diagnostic or therapeutic gastroscopes. Perianastomotic collections were explored with the endoscope if possible and necrotic debris was flushed and suctioned. The collection was imaged using contrast opacification under fluoroscopy. Leaks were then intubated using a straight catheter (Tandem, Boston Sci-

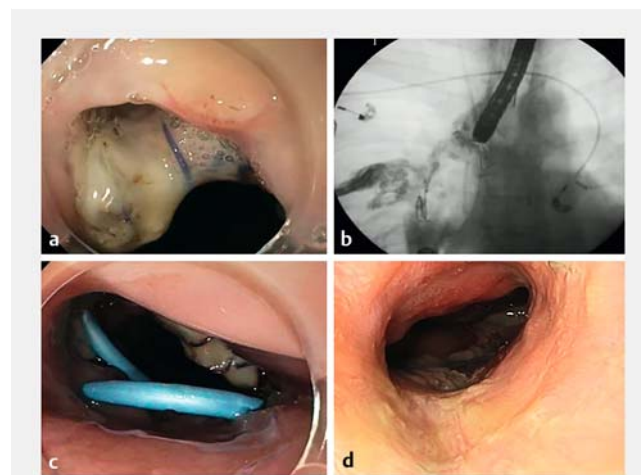
entific, Massachusetts, USA) and a guidewire (Jagwire, Boston Scientific, Massachusetts, USA), over which either one or two double-pigtail stents (7–10 Fr, 3–5 cm; Solus, Cook, Limerick, Ireland or Advanix, Boston Scientific) were inserted (► Fig. 1).

Pigtail stent change was performed every 3–4 weeks. Endoscopic healing of the leak was ascertained when the pigtail stents had spontaneously migrated into the digestive tract, or when opacification of the fistulous tract after EID extraction did not show any residual collection. Oral water intake was allowed after the first EID placement. Parenteral or enteral nutrition (via a nasojejunal/duodenal feeding tube or a jejunostomy) was added. Patients were transferred to post-acute care hospitals in order to adapt the artificial nutrition and to monitor for septic signs until the second endoscopy 3–4 weeks later. After the second endoscopy, patients were authorized to resume oral soft food, return home, and perform normal daily activities. Pigtail stent changes were performed on an outpatient basis, whenever possible.

### EVT technique

The technical modalities of EVT and low negative-pressure EVT have been reported elsewhere [6, 10]. EVT consists of a drain with an open-pore sponge cylinder at the end, which can be adjusted for smaller leaks. EVT can be placed intracavitarily or intraluminally close to the leak site.

In this cohort, patients were treated with low negative-pressure EVT (between  $-20$  and  $-50$  mmHg). Pre-prepared EVT sets (Eso-SPONGE, Braun B Melsungen, Germany; size 2: external overtube size 19 mm) were used and negative pressure was applied using an external suction pump (for example Medela Thopaz, Medela Medizintechnik, GmbH & Co. Handels KG, Germany). Wound cavities were carefully examined endoscopically



► **Fig. 1** Example treatment sequence for endoscopic internal drainage using double-pigtail stents for an anastomotic leak after esophagectomy showing: **a** a large anastomotic defect at the index endoscopy, which was performed for severe sepsis and purulent drainage on postoperative day 7; **b** insertion of a catheter and opacification of the collection under fluoroscopy; **c** placement of two double-pigtail stents; **d** final appearance with complete healing of the anastomotic defect after pigtail stent extraction.

using a standard gastroscope, whenever possible. For defects smaller than 2 cm, EVT was placed intraluminally. The Eso-SPONGE was inserted into the esophagus via a transorally introduced overtube and its positioning was adjusted using a standard grasper (► Fig. 2). The sponge was changed every 3–4 days. Patients were hospitalized during the whole EVT course.

Oral intake was possible with low amounts of clear fluids or, where a nasogastric tube was placed, via enteral feeding.

## Statistical analysis

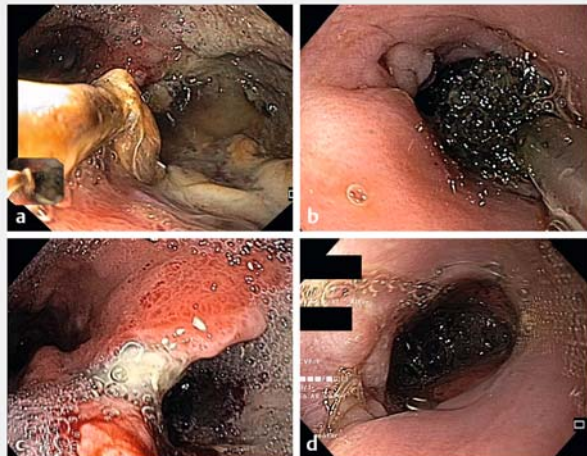
In addition to descriptive analysis for patient characteristics, univariate comparative analysis for patient characteristics and treatment-related data were performed using Fisher's exact test for categorical variables and the Mann–Whitney U test for numeric variables. The significance level was set to  $\alpha=5\%$ . All analyses were performed using R Data analysis software (version 3.4.0; R Core Team 2018). All data are displayed as median and interquartile range (IQR).

The primary outcome was overall endoscopic treatment success. Secondary outcomes were the number of endoscopies needed for leak closure, total treatment duration, morbidity, mortality, and anastomotic stricture rates.

## Results

### Patient characteristics

A total of 35 patients in the EID group and 27 patients in the EVT group were analyzed in this study. The characteristics of these patients are displayed in **Table 1 s** (see online-only Supplementary Material).



► **Fig. 2** Example endoscopic images of endoscopic vacuum therapy showing: **a** leakage from a defect of > 1 cm at the esophago-gastric anastomosis with a paraesophageal cavity; **b** Eso-SPONGE insertion and positioning with a standard grasper; **c** appearance of initial therapy, with a reduction in the purulent fluid and evidence of mucosal granulation; **d** final appearance with complete mucosal healing.

## Leaks and treatment

The description of the leak and its endoscopic treatment is presented in **Table 2 s**. Leaks measuring 5–20 mm accounted for 80% of leaks in the French cohort and 81.5% of leaks in the German cohort.

Overall endoscopic treatment success was 100% ( $n=35/35$ ; 95%CI 90%–100%) vs. 85.2% ( $n=23/27$ ; 95%CI 66.3%–95.8%) in the EID vs. EVT groups, respectively ( $P=0.03$ ), after a median (IQR) of 2 (2–3) vs. 3 (2–6.5) endoscopic procedures in the EID vs. EVT groups, respectively ( $P=0.003$ ), and a median (IQR) treatment duration of 42 days (28–60) vs. 17 days (7.5–28) in EID vs. EVT group, respectively ( $P<0.001$ ).

The primary treatment success rate was 91.4% ( $n=32/35$ ; 95%CI 76.9%–98.2%) vs. 74.1% ( $n=20/27$ ; 95%CI 53.7%–88.9%) in the EID vs. EVT group, respectively ( $P=0.09$ ). In three patients treated with EID, OTS clips were used for final leak closure, while one fibrin glue injection, one OTS clip, and one SEMS placement were used to obtain closure in three patients in the EVT group.

No major procedural complications were documented in the EID or EVT groups. Two patients (7.4%) died from multiorgan failure in the EVT group.

## Follow-up

Follow-up data are presented in **Table 3 s**. Data on follow-up was available from 22/35 patients in the EID group for a median (IQR) of 122 days (92–248) and 13/27 patients in the EVT group for a median (IQR) of 316 days (200–452;  $P=0.07$ ).

## Discussion

This is the first study to compare EID and EVT for the endoscopic treatment of leaks after oncologic upper GI surgery. We observed comparable primary efficacy for the two techniques (91.4% vs. 74.1% in the EID vs. EVT groups, respectively;  $P=0.09$ ), and a significantly higher efficacy of the endoscopic treatment when additional treatment modalities were introduced (100% vs. 85.2% in EID vs. EVT groups, respectively;  $P=0.03$ ). While EID was associated with a significantly longer treatment duration, EVT required more endoscopic procedures, owing to iterative sponge replacements. Of note, neither treatment resulted in an increased rate of anastomotic strictures.

Our study has several limitations. First, the limited sample size and retrospective design, which is often associated with patient selection bias and loss to follow-up.

Second, the multicenter nature of the study induced a heterogeneity in patient management, exemplified by the differing proportions of Ivor Lewis esophagectomies. However, because of the limited sample size, we did not have enough statistical power to adjust for this added variation in our analyses. No significant differences were found concerning most baseline variables. Information such as the anastomotic leak rate at each center, number of successful surgical reinterventions, and other successful endoscopic methods (e.g. SEMS placement) were not available.

Third, we did not specifically record information on large (>50% of the circumference) anastomotic defects, which are excellent indications for EVT and relative contraindications for EID, owing to the risk of pigtail stent migration [11]. Therefore, it is possible that EVT would yield better results for the largest anastomotic defects.

The duration of hospital stay was not analyzed. While EVT requires patients to stay hospitalized during the entire treatment, EID offers the theoretical advantage of outpatient management. However, patients in the EID group were typically admitted to post-acute care hospitals, in order to monitor artificial nutrition and to observe for signs of sepsis until the second endoscopy, which was performed 3–4 weeks later. After the second endoscopy, patients were allowed to resume oral soft food and return home in most cases, and were then managed as outpatients. Although the exact cumulative length of hospital stay was not available for the patients in the EID group, most of them spent more than a month admitted to a healthcare facility.

The timing of EID exchange is an ongoing discussion. EID stent changes were initially performed every 3–4 weeks, in analogy to esophageal stents that need to be replaced every 4 weeks to prevent tissue ingrowth, and also to maintain stent patency, particularly in cases where only one double-pigtail stent was placed. However, other teams have reported longer time periods before double-pigtail stent replacement [12].

Future studies need to compare low negative-pressure EVT with standard EVT and also to investigate the combination of EID and EVT. In conclusion, EID and EVT are safe and highly effective treatment options for anastomotic leaks after oncologic upper GI surgery.

## Acknowledgments

We sincerely thank our study nurse Ms. Kathrin Salzmann for data recruitment and analysis.

## Competing interests

The authors declare that they have no conflict of interest.

## References

- [1] Rutegard M, Lagergren P, Rouvelas I et al. Intrathoracic anastomotic leakage and mortality after esophageal cancer resection: a population-based study. *Ann Surg Oncol* 2012; 19: 99–103
- [2] Rutegard M, Lagergren P, Rouvelas I et al. Surgical complications and long-term survival after esophagectomy for cancer in a nationwide Swedish cohort study. *Eur J Surg Oncol* 2012; 38: 555–561
- [3] Blencowe NS, Strong S, McNair AG et al. Reporting of short-term clinical outcomes after esophagectomy: a systematic review. *Ann Surg* 2012; 255: 658–666
- [4] Watanabe M, Miyata H, Gotoh M et al. Total gastrectomy risk model: data from 20,011 Japanese patients in a nationwide internet-based database. *Ann Surg* 2014; 260: 1034–1039
- [5] Rodrigues-Pinto E, Morais R, Macedo G et al. Choosing the appropriate endoscopic armamentarium for treatment of anastomotic leaks. *Am J Gastroenterol* 2019; 114: 367–371
- [6] Jung CFM, Muller-Dornieden A, Gaedcke J et al. Impact of endoscopic vacuum therapy with low negative pressure for esophageal perforations and postoperative anastomotic esophageal leaks. *Digestion* 2020: doi:10.1159/000506101
- [7] Pequignot A, Fuks D, Verhaeghe P et al. Is there a place for pigtail drains in the management of gastric leaks after laparoscopic sleeve gastrectomy? *Obes Surg* 2012; 22: 712–720
- [8] Donatelli G, Dumont JL, Cereatti F et al. Treatment of leaks following sleeve gastrectomy by endoscopic internal drainage (EID). *Obes Surg* 2015; 25: 1293–1301
- [9] Donatelli G, Dumont JL, Cereatti F et al. Endoscopic internal drainage as first-line treatment for fistula following gastrointestinal surgery: a case series. *Endosc Int Open* 2016; 4: E647–E651
- [10] Loske G, Muller CT. Tips and tricks for endoscopic negative pressure therapy. *Chirurg* 2019; 90: 7–14
- [11] Wedi E, Schuler P, Kunsch S et al. Individual endoscopic management of anastomotic insufficiency after esophagectomy for esophageal squamous cell carcinoma and creation of a neostomach. *Endoscopy* 2018; 50: E69–E71
- [12] Bouchard S, Eisendrath P, Toussaint E et al. Trans-fistulary endoscopic drainage for post-bariatric abdominal collections communicating with the upper gastrointestinal tract. *Endoscopy* 2016; 48: 809–816