

# Highly exuding non-healing leg ulcers: a surmountable challenge

Clinical benefits of the Zetuvit Plus superabsorbent dressing family under compression



## Foreword

Leanne Atkin

S3

## Venous leg ulcer management: overcoming clinical challenges and promoting shared care

Brenda King

S4

## Zetuvit Plus and Zetuvit Plus Silicone superabsorbent polymer (SAP) dressings: effectiveness under compression therapy

S12

### Case studies 1–4

S13–19

Sian Davies; Delma Duffus-Grovel; Helen Meagher and Shauna Chaplin

This article is reprinted from British Journal of Nursing • VOL 30 NO 5 (SUPPL 1) March 2021

Cover image: Adobe Stock

Declaration of interest: this supplement was commissioned and supported by HARTMANN. Leanne Atkin, Shauna Chaplin, Sian Davies, Delma Duffus-Grovel, Brenda King and Helen Meagher are all independent consultants who were paid a fee for their contributions. The authors have no other interests to declare.

Published by: MA Healthcare Ltd, St Jude's Church, Dulwich Road, London, SE24 0PB, UK  
Tel: +44 (0)20 7501 6726. Web: [www.markallengroup.com](http://www.markallengroup.com)

©MA Healthcare Ltd 2021

Published on behalf of HARTMANN. All rights reserved. No reproduction, transmission or copying of this publication is allowed without written permission. No part of this publication may be reproduced, stored in a retrieval system, or transmitted in any form or by any means, mechanical, electronic, photocopying, recording, or otherwise, without the prior written permission of MA Healthcare Ltd, or in accordance with the relevant copyright legislation.

Although the editor, MA Healthcare Ltd and HARTMANN have taken great care to ensure accuracy, neither MA Healthcare Ltd nor HARTMANN will be liable for any errors of omission or inaccuracies in this publication.

Managing director: Anthony Kerr ([anthony.kerr@markallengroup.com](mailto:anthony.kerr@markallengroup.com))

Associate publisher, medical education and editor: Tracy Cowan

Head of Projects: Camila Fronzo

Project manager: Angela Shaw

Designer: Fonthill Creative



Lower limb ulceration continues to represent a substantial burden for patients and healthcare systems. Unfortunately, its incidence is increasing at a rather alarming rate. There has been a 37% increase in the prevalence of lower limb ulceration in the UK over the past few years, rising from 730 000 in 2012/2013 to over 1 million people in 2017/2018, which equates to 2% of the adult population (Guest et al, 2020). More than half of these (560 000 patients) had a recorded diagnosis of venous ulceration.

It is widely accepted that the recommended evidence-based management of patients with venous ulceration is therapeutic compression therapy, where the compression system provides at least 40 mmHg pressure at the ankle. However, patient adherence to compression therapy is always a subject of concern. Health professionals need to ensure they do all they can to build therapeutic relations with patients and explore all the known determinants that impact on a patient's ability to use compression, including ensuring that they are aware of the reasons for compression, that they listen to the patient's aesthetic and cosmetic wishes before choosing a compression system and that physical factors, such as pain, are addressed. A further physical factor linked to issues with adherence is leakage of exudate (Moffatt et al, 2009). Appropriate and successful management of exudate is a key component of enabling effective care. The importance of exudate management is recognised by the National Wound Care Strategy Programme (NWCSP), which states that a primary dressing with 'sufficient absorbency' should be used (NWCSP, 2020).

The NWCSP also advises that, when appropriate, people with leg and foot wounds should be supported to self-care. Supported self-management is part of the NHS Long Term Plan (NHS, 2019), which promotes encouraging patients to manage their own health and care. The Plan also urges health professionals to tailor their approaches to the individual patient's needs and preferences, and to think about 'what matters' to them.

The pandemic has allowed supported self-management to become widely established within wound care across the UK. It is important we do not forget the day-to-day personal impact of living with a wound, which is exacerbated by leakage of exudate. Living with a non-healing wound is responsible for a number of psychosocial problems, including increased feelings of loss of power, helplessness, depression and social isolation (Vishwanath, 2014).

Poor exudate management will not only affect a patient's quality of life and ability to use compression, but will also impact on angiogenesis and healing rates

(Drinkwater et al, 2002), affect the integrity of periwound skin and increase the risk of infection.

The day-to-day impact on the patient must be the primary objective of management, but there also needs to be consideration of healthcare resources. Exudate management presents a huge burden to NHS services, both in terms of direct costs and service provision, with reports of up to 55% of community workload related to the management of leaking lower leg ulcers (Morgan and Thomas, 2018). Supporting patients to self-manage will help reduce the burden on the NHS, allowing and enabling patients to take control of their own condition, such as by changing dressings when they are leaking, malodorous or simply to fit into their lifestyle, such as just after having a shower, all of which will have a positive impact on their quality of life.

The cornerstone of effective exudate management of the lower limb is compression therapy, but this must be delivered in parallel with the application of an appropriate wound dressing—that is, one that will effectively control exudate and prevent leakage and strikethrough, while maintaining an optimum wound-healing environment. Most importantly, it must be easy to use, allowing patients who wish to self-manage to do so easily. This supplement describes how use of the Zetuvit Plus® family of superabsorbent dressings has enabled this approach.



Drinkwater SL, Smith A, Sawyer BM, Burnand KG. Effect of venous ulcer exudates on angiogenesis in vitro. *Br J Surg*. 2002; 89(6):709–13. <https://doi.org/10.1046/j.1365-2168.2002.02085.x>

Guest JF, Fuller GW, Vowden P. Cohort study evaluating the burden of wounds to the UK's National Health Service in 2017/2018: update from 2012/2013. *BMJ Open*. 2020; 10(12):e045253. <https://doi.org/10.1136/bmjopen-2020-045253>

Moffatt C, Kommala D, Dourdin N, Choe Y. Venous leg ulcers: patient concordance with compression therapy and its impact on healing and prevention of recurrence. *Int Wound J*. 2009; 6(5):386–93. <https://doi.org/10.1111/j.1742-481X.2009.00634.x>

Morgan K, Thomas M. The development of a "wet leg" pathway for chronic oedema. *Int J Palliat Nurs*. 2018; 24(1):40–6. <https://doi.org/10.12968/ijpn.2018.24.1.40>

NHS. The NHS Long Term Plan, 2019. <https://tinyurl.com/b7fjx4tz> (accessed 23 February 2021)

National Wound Care Strategy (NWCSP). Lower limb recommendations for clinical care. 2020. <https://tinyurl.com/ynm936cj>

Vishwanath V. Quality of life: Venous leg ulcers. *Indian Dermatol Online J*. 2014; 5(3):397–9. <https://doi.org/10.4103/2229-5178.137828>

**Leanne Atkin PhD, MSc, RGN**

Lecturer Practitioner, University of Huddersfield and Vascular Nurse Consultant, Pinderfields Hospital, Wakefield, UK

# Venous leg ulcer management: overcoming clinical challenges and promoting shared care

The huge socioeconomic burden of managing non-healing venous leg ulcers (VLUs) has led to the development of a national pathway for the assessment and treatment of these wounds. Developed by the National Wound Care Strategy Programme, the pathway promotes the concept of shared care, where appropriate, to empower patients, promote concordance and reduce costs. As many VLUs produce high volumes of fluid, this requires an effective strategy for exudate management. This article describes how use of superabsorbent dressings can lock fluid within their structure, thereby protecting both the wound bed and periwound skin

The management of venous leg ulcers (VLUs) has been under the spotlight recently. Recommendations for managing lower leg wounds have been published on the National Wound Care Strategy Programme (NWCSP) website (NWCSP, 2020). In addition, as a result of the COVID-19 pandemic, there has been a drive to promote self-care or shared care and virtual consultations for patients with wounds, including VLUs (Adderley, 2020; Dhoonmoon and O'Neill, 2020). This article considers the assessment and management of VLUs, in line with the NWCSP recommendations, and discusses some of the clinical challenges faced, in particular exudate management. It also explores the concept of shared care and self-care/management of VLUs, describing how this can promote concordance and aid healing.

## Venous leg ulceration

A wound on the lower leg that fails to heal is usually a direct result of an underlying disordered circulation, whether venous, arterial or both, or, in some cases, a compromised microcirculation that may result from an autoimmune disease or inflammatory disorders (National Institute for Health and Care Excellence (NICE), 2020a). Trauma is often involved in the development of an ulcer. Initially, the trauma may seem minor, such as a skin tear or haematoma, but it may fail to heal due to the altered physiology (NHS England, 2017).

The most common cause of leg ulceration is incompetent venous circulation (NHS, 2019a). The movement of venous blood from the lower leg up through the veins against gravity is reliant on muscle pumps in the foot, ankle and calf. As the muscles contract, they squeeze blood into the deep veins, forcing it up towards the heart (Figure 1). The direction of flow is controlled by one-way valves, which close to prevent backflow of venous blood back down the vein (Tansey et al, 2019).

When there is damage to this system, the valves become incompetent and fail to close effectively, allowing

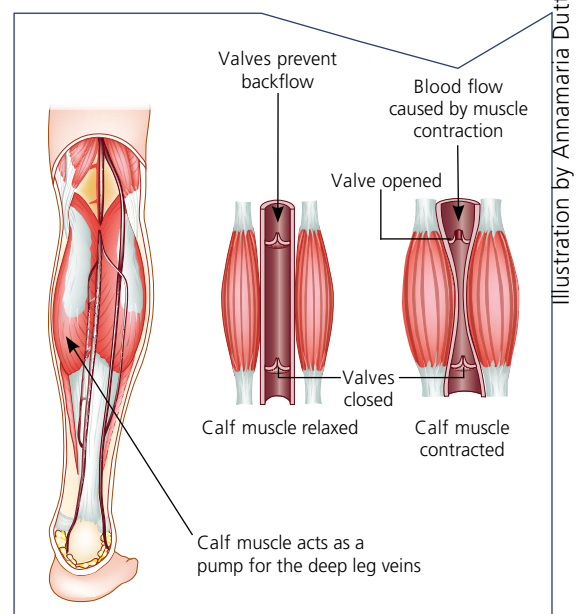


Figure 1. The calf muscles contract, squeezing blood up through the deep veins towards the heart

**Brenda King**  
Independent Nurse Consultant, Tissue Viability,  
Wound Care Connections

backflow of blood, which engorges the superficial veins. This creates abnormally high pressure in the superficial vein network (Anderson, 2008). This rise in venous pressure allows fluid to leak into the interstitial spaces and reduces the effectiveness of the lymphatic system and capillaries in removing it (Levick and Michel, 2010).

This increase in interstitial fluid and accompanying osmotic pressure encourages more fluid to leak from the capillary, resulting in further oedema (Waugh and Grant, 2018). The congestion in the tissue bed impairs the quality of the skin and can cause venous eczema and ulceration (Hofman, 2010).

### Providing a leg ulcer care service

A hard-to-heal wound has been defined as one that fails to heal with standard therapy in an orderly and timely manner (Vowden, 2011). The lower leg is the most prevalent site for hard-to-heal wounds (Ousey et al, 2013; Guest et al, 2015).

In an assessment of UK prevalence data for 2012/13 undertaken to calculate the health economic burden of wounds, Guest et al (2015) found there were 730 000 leg ulcers, affecting approximately 1.5% of the adult population. More worryingly, Guest et al suggested that only 16% of patients with a foot or leg wound had had a Doppler assessment to establish the efficiency of their arterial blood flow. Further analysis of this burden-of-wounds data, published 2 years later, suggested the number of hard-to-heal wounds could be increasing by 11% per annum (Guest et al, 2017).

A follow-up paper with data for 2017/18 found that these figures had worsened in the interim period (Guest et al, 2020). UK prevalence of patients with leg ulcers for 2017/18 had increased to over 1 million (1 054 000), with 2% of the adult population having a wound on the lower limb, of whom 1% had a VLU (Guest et al, 2020). There was a slight fall in the proportion of patients with a wound on the lower leg who had a reported Doppler ankle brachial pressure index (ABPI), which was now 15%. Worryingly, over 90% of patients with a VLU were prescribed compression therapy. Finally, Guest et al (2020) reported that the healing rate of VLUs and mixed-aetiology leg ulcers decreased by 21% and 29% respectively in 2017/18, when compared

with 2012/13, whereas increases were reported for diabetic foot ulcers and pressure ulcers.

The low level of Doppler assessments cited in these papers suggests that a clear diagnosis of the underlying aetiology had not been established, which raises the question of whether the correct treatment for the underlying aetiology was being administered. Without correct treatment, an ulcer on the lower limb could fail to heal, increasing management costs and reducing patient quality of life. It is possible that some of this increase reflects lack of healing due to inappropriate treatment.

The findings by Guest et al fuelled the ongoing national debate about the provision of wound care and, in particular, VLU management, where care was often considered suboptimal.

This led to the establishment of the NWCSP, whose mission is to 'implement a consistently high standard of wound care across England by reducing unnecessary variation, improving safety and optimising patient experience and outcomes'. Recommendations for the management of wounds on the lower leg have been published on the NWCSP website, alongside a minimum dataset for lower leg assessment and resources for health professionals and patients relating to the management of these wounds (NWCSP, 2020).

### NWCSP recommendations for leg ulcer care

Health professionals should follow the evidence-based recommendations for lower leg wounds published on the NWCSP website. These detail the initial care that should be offered to all people presenting for the first time with any lower leg wound. A leg ulcer is defined in the recommendations as: 'a wound on the leg which originates on or above the malleolus' (NWCSP, 2020).

#### Initial presentation

A person with a leg ulcer may present to healthcare services via several different routes, such as general practice, emergency departments or walk-in centres, where the staff may not be experienced in leg assessment and, therefore, therapeutic treatment is often delayed (NHS England, 2017). As the majority of leg ulcers have a venous component (NHS, 2019a), the NWCSP considers



it best practice to start with some reduced compression therapy at the initial presentation, without undertaking a full leg ulcer assessment and calculating the ABPI (British Lymphology Society (BLS), 2019). It is thought this early proactive management may reduce the risk of chronicity. The patient should be screened for any 'red flags', which include:

- Acute infection
- Symptoms of sepsis
- Acute or chronic limb-threatening ischaemia
- Suspected acute deep vein thrombosis
- Suspected skin cancer.

If any of these 'red flags' appear to be present, they should be treated or escalated immediately to the appropriate service. For example, a patient with suspected acute limb ischaemia should be referred to vascular services and a patient with possible sepsis or acute deep vein thrombosis should be admitted or referred to secondary care (Conte et al, 2019; NICE, 2019; NHS, 2019b; NICE, 2020a; 2020b; 2020c).

If there are no 'red flags' present at the initial visit, the health professional should:

- Implement wound bed preparation
- Cleanse the periwound and limb skin
- Apply an emollient as required
- Apply a simple, low-adherent wound contact dressing with sufficient absorbency
- Use mild compression therapy (up to 20 mmHg pressure at the ankle) (World Union of Wound Healing Societies (WUWHS), 2008).

The compression therapy may be in the form of compression hosiery, wraps or bandages. Where appropriate, the person should be supported to self-care.

With self-care, the person receives ongoing support and education from health professionals to help them to manage their leg ulcer themselves. Thus, this is also known as shared care. Clinical decision-making is shared, but the person is empowered to undertake their own dressing changes and apply their compression themselves, according to their individual needs. It is thought that such empowerment increases motivation, thereby promoting concordance and adherence to treatment, and therefore healing outcomes. This has particularly come into its own during the COVID-19 lockdown, when access to people's homes has been restricted. Benefits to a stretched NHS come in the form of cost savings created by reducing the frequency and duration of home visits and other patient consultations, increased potential to allocate nursing resources to individuals most in need and improved healing outcomes (Dowsett, 2021). Shared care is most suitable for patients who have uncomplicated leg

ulcers with low to moderate volumes of exudate.

The main categories of compression therapy are:

- Multicomponent bandaging (usually four-layer systems)
- Short-stretch/inelastic bandaging systems (usually two-layer systems)
- Hosiery kits
- Wraps.

As such, use of compression hosiery kits and wraps may be more suitable for self-care, although, for hosiery, the presence of poor skin integrity, significant oedema and a patient's lack of dexterity may inhibit their use (Atkin, 2019).

### **Next step: referral to a wound specialist for assessment**

Once immediate care has been provided at the initial presentation, a referral should be made within 24 hours to a health professional with advanced wound-care capabilities and competencies, who should see the patient within 14 days (NWCSF, 2020).

At this appointment, the person should receive a full holistic assessment, including an ABPI using Doppler ultrasound (Scottish Intercollegiate Guidelines Network (SIGN), 2010; NWCSF, 2020) to exclude arterial disease. This is important to determine if it is safe to apply the level of compression (strong—40 mmHg at the ankle (WUWHS, 2008) necessary to reverse venous hypertension and support wound healing. A vascular referral should also be considered in order to assess whether the patient is suitable for endovenous laser therapy (Gohel et al, 2018). The lower limb pathway is illustrated in *Figure 2*.

As well as providing the recommended compression therapy required to reverse venous hypertension, it is important to consider patient symptoms that are associated with a VLU.

### **Exudate: a clinical challenge in venous leg ulcer management**

People presenting with a VLU often have symptoms, such as pain, exudate and malodour, that significantly impact on their quality of life. It is essential that steps are taken to minimise these (Benbow and Stevens, 2010; Dowsett, 2012; NHS, 2019a).

Both pain and malodour should be monitored carefully and managed effectively. Any malodour could be linked to a wound (Nix, 2016) and may be due to a number of reasons (WUWHS, 2019), such as the presence of microorganisms (Edwards-Jones, 2018). Certain bacterial species and pathogens commonly found in wounds, such as *Pseudomonas*, anaerobes and group A haemolytic

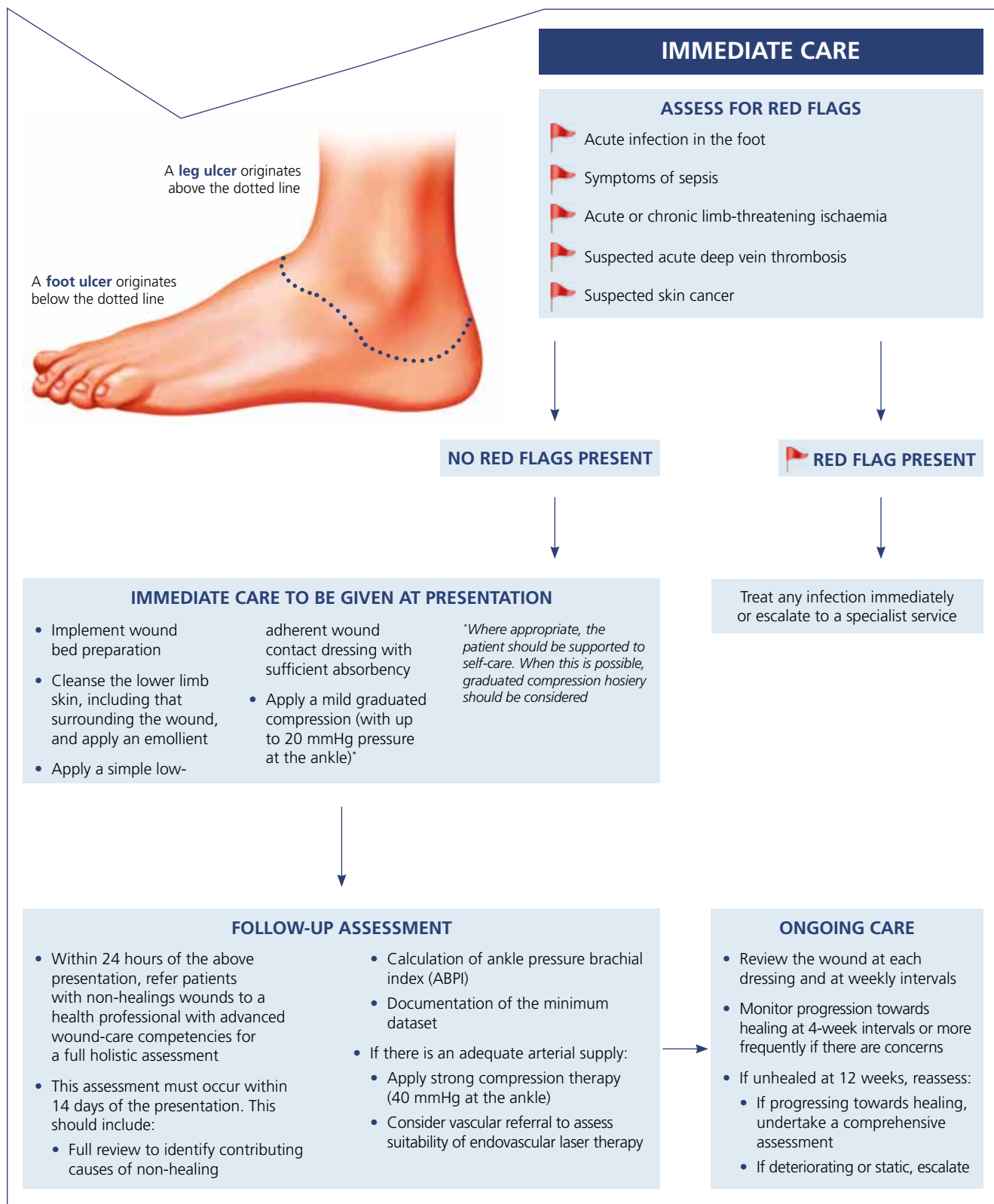


Figure 2. Summary of the National Wound Care Strategy Programme lower limb pathway

Table 1. Differences between exudate produced by acute and hard-to heal wounds

What is wound exudate?	
Injured tissue releases a range of enzymes and mediators that increase fluid (exudate) production at the wound site. Exudate is defined as fluid that leaks from a wound (Romanelli et al, 2010)	
Characteristics of exudate from acute wounds	Characteristics of exudate from hard-to-heal wounds
<ul style="list-style-type: none"> <li>• Clear, pale and amber-coloured</li> <li>• Contains electrolytes, nutrients, proteins, inflammatory mediators and metalloproteinases that support wound healing (Lloyd Jones, 2014)</li> <li>• Bathes the wound and so helps create a moist environment that aids cell migration and movement of growth factors into the wound bed (Adderley, 2008; Romanelli et al, 2010; Gardener, 2012), thereby supporting healing</li> <li>• The exudate level is generally higher during the inflammatory phase of repair and reduces as healing progresses (Schultz et al, 2011)</li> </ul>	<ul style="list-style-type: none"> <li>• Contains more harmful elements, such as higher levels of inflammatory molecules</li> <li>• These stimulate the production of enzymes (metalloproteinases, MMPs) that degrade proteins and growth factors</li> <li>• This hinders cell proliferation and reduces growth factor production, enabling the MMPs to damage the new extracellular matrix (Romanelli et al, 2010; Dissemond et al, 2013)</li> <li>• This creates further inflammation and, as a consequence, increased exudate levels (Schultz et al, 2011)</li> </ul>

streptococcus. According to Edwards-Jones (2018), malodour is associated with increased bioburden, and ‘could possibly’ be a first indicator of wound infection.

Wound exudate provides an ideal environment for bacterial proliferation, and so excess levels are associated with malodour, prolonged inflammation, tissue breakdown and pain. Therefore, excess exudate often has a negative impact on quality of life (Benbow and Stevens, 2010; Gethin et al, 2014) and can be a cause for clinical concern, requiring careful management.

However, not all exudate is damaging. Acute wound exudate plays an essential role in wound healing, whereas exudate from hard-to-heal wounds impairs it. Therefore, it is necessary to have a good understanding of the role of exudate and how it differs in acute and hard-to-heal wounds. *Table 1* describes some of the main differences between exudate from these wound types.

### Fluid from hard-to-heal wounds

#### Characteristics

Hard-to-heal wounds may produce copious amounts of exudate, with different factors influencing its volume and consistency, such as infection and biofilm, comorbidities including cardiac or renal failure, malnutrition and low serum albumin levels (WUWHS, 2019). Anatomical location also plays a role: wounds on the lower leg will produce high levels of exudate as a result of increased oedema due to limb dependency and associated venous

hypertension (Adderley, 2008; Romanelli et al, 2010; Gardener, 2012; Mortimer and Rockson, 2014).

Exudate from hard-to-heal wounds may be viscous, purulent, cloudy and discoloured, as well as possibly malodorous (Vowden et al, 2015). All of these characteristics should be documented in the minimum data set now required for wound assessment (Coleman et al, 2017). Any changes in exudate characteristics should prompt a review of the wound and re-evaluation of its treatment, as exudate provides vital clues about potential problems, such as bacterial contamination or infection (Romanelli et al, 2010).

#### Effects on periwound skin

Excess exudate also can be harmful to the periwound skin (Wounds UK, 2013). Therefore, careful attention should be paid to skin care.

People with venous hypertension often have pre-existing poor skin quality on their lower legs (Wounds UK, 2013), as some essential functions of the skin are lost or damaged. Skin around the ulcer may be dry, irritated or flaky (NHS, 2019a), possibly with small cracks or fissures, making it easier for exudate to cause problems, while also allowing access for irritants and bacteria, which may cause dermatitis and infection (Langøen and Bianchi, 2013). The skin therefore requires protection from exudate; regular application of an emollient will help maintain a healthy skin barrier (Wounds UK, 2013).

#### Psychosocial effects

As well as impairing wound healing, if poorly managed, excess exudate may lead to social isolation, as the person might feel unclean if it is visible or leaks through the dressing or bandages, or worry about offensive odour from the wound. This can also lead to low mood (Lindahl et al, 2007; Ousey and Roberts, 2017).

Clearly, if the health professional does not prescribe the correct underlying treatment and an effective dressing, the person may experience a reduced quality of life and be labelled non-concordant if they remove exudate-soaked dressings or bandages. Furthermore, if there is a risk of exudate soiling their bedding, they may take to sleeping in a chair with their legs dependent, which will contribute to further gravitational oedema, increasing exudate levels still further (Romanelli et al, 2010).

### Management

#### Assessing the cause

When treating someone with a high level of wound exudate, it is essential that factors influencing the high output are identified in order to treat the cause, rather



than simply choosing a dressing with which to ‘mop it up’. For example, if compression therapy is not used on a VLU or is not applied at an effective level to reverse the venous hypertension, exudate levels will remain high because the oedema and venous hypertension are not being managed (Waugh and Grant, 2018).

Treatment of VLUs, therefore, should aim to achieve therapeutic levels of compression therapy. However, oedematous tissue of other aetiologies, such as renal failure, will produce increased levels of exudate, as described earlier. As such, any tissue oedema requires investigation and appropriate treatment.

When there is invading bacteria in a wound, an increased inflammatory response will occur and the exudate volume will increase as a result (WUWHS, 2019). In these circumstances, treatment should aim to remove or reduce the bacterial load. Any foreign particles in the wound will result in an inflammatory response (WUWHS, 2019), and the exudate level will increase in an attempt to remove the irritant. Foreign particles may comprise dressing or bandage residue or even hair (human or pet); these will require removal and wound cleansing.

### Dressing selection

Once all underlying causes of increased exudate have been addressed, careful dressing selection is important. It is essential to use a product that can manage wound exudate effectively and, in particular, can avoid leakage onto clothing and bedding. The dressing should protect the wound bed, provide the ideal environment for healing and protect the periwound skin. It should be atraumatic to remove, easy to use and, most importantly, comfortable and acceptable to the patient (Dowsett, 2011; Vowden, 2011).

A further consideration when choosing a dressing for use underneath compression therapy is its ability to retain the exudate within its matrix. Many absorbent dressings consist of hydrophobic (repels fluid) and hydrophilic (attracts fluid) foam. The hydrophobic skin contact layer repels absorbed moisture, which thus travels to the dressing’s hydrophilic core, where it is trapped. Although an absorbent dressing may absorb fluid like a sponge, it may not be able to lock it into its core, and the compression therapy may squeeze the fluid out (Wounds UK, 2013).

A group of dressings, referred to as superabsorbers, have an absorbent core containing polyacrylate polymers, which take up the fluid and form a gel that may change shape under pressure but will not allow fluid to escape (Wounds UK, 2013). As a result of this action, bacteria and harmful metalloproteinases, which are detrimental to

healing, are sequestered from the exudate and trapped in the gel (Sweeney et al, 2012; Browning et al, 2016). Therefore, a superabsorbent dressing reduces the risk of the harmful elements of chronic wound fluid coming into contact with the wound bed and periwound skin.

In the past, before evidence was produced on the effectiveness of compression hosiery in treating venous hypertension (Ashby et al, 2014), this condition was generally managed using multilayer bandages, often with a first layer of orthopaedic wool. At the time, it was considered that the layers of the multilayer bandage system were helpful in absorbing exudate (Hopkins, 2006). Clearly, hosiery and wrap compression systems are not capable of offering much in the way of exudate absorption. Therefore, a dressing’s ability to manage exudate under these systems is an important requirement. Furthermore, the dressing must be easy to use underneath the system, particularly given the increased emphasis on self-management. Potentially more people will be treated with this method in the future, and making sure the dressing is right for shared-care will be part of the overall management plan.

### Shared care, self-management and patient empowerment

If Guest et al’s (2017) calculations are correct and the number of hard-to-heal wounds is increasing, this would suggest that the size of the healthcare workforce needs to increase, too. However, evidence indicates that the nursing workforce is reducing (Buchan et al, 2019). Therefore, it will be essential to improve outcomes with earlier intervention and appropriate management of venous hypertension.

To manage the increased number of hard-to-heal wounds and, in line with the NHS Long Term Plan to increase shared care (NHS, 2019c) and support people to manage their own health (Ham et al, 2018), patient empowerment, shared care and self-management should be encouraged, where possible.

When considering self-management of VLUs, a clear plan or pathway needs to be developed and agreed with the person, as opposed to giving them a list of instructions or rules (Rollnick et al, 2008). It is, of course, necessary to understand the capacity and capability of the individual, or their carer or relative, to engage in a shared care self-management plan (Wounds UK, 2018). Factors that contribute to effective shared care and self-management include:

- Accurate holistic assessment by a suitably trained health professional, who should be able to recognise when self-management may not be appropriate—for

example, in people with mixed-aetiology leg ulcers or with comorbidities that may increase clinical risk if closer monitoring is not maintained

- A therapeutic relationship or partnership between the health professional and patient (Tandler, 2016; Wounds International, 2016)
- The person's capacity to undertake self-management and their willingness to perform their own wound care (Wounds UK, 2018)
- An understanding of the person's lifestyle, activities of daily living and what is important to them. The management plan needs to fit in with their lifestyle (Yarwood-Ross and Haigh, 2012)
- An agreed, effective treatment plan for the underlying venous hypertension
- The person must be able to apply the treatment. People requiring compression bandaging are less likely to be able to self-manage
- Awareness of factors that make compression hosiery unsuitable, such as the presence of gross oedema, abnormal limb shape or poor skin quality (NWCSP, 2020). The patient should have the dexterity to be able to apply the compression system, or be supported by the provision of donning and doffing aids, or have available carer help (Atkin, 2019)
- The person should be provided with an adequate supply of dressings that are easy for them to use. They should be advised on the dressing-change frequency and how to remove and apply them
- Provision of information and education to patients on the rationale for compression (Wounds International, 2016)
- Provision of leaflets with information appropriate for the individual, or signposting them to sources of such information (Tandler, 2016)
- The person must know what aspects of their wound they need to monitor, record and/or report
- Provision of details to the person on who to contact and how when they have a concern (Wounds International, 2016).

## Conclusion

Wound care and the management of hard-to-heal wounds, in particular, is an important aspect of health care. Hard-to-heal wounds are predominantly located on the lower leg, with the most prevalent being VLU. These ulcers have a detrimental effect on quality of life, making it essential that a person seeking help for a lower leg wound has prompt and effective care to reduce the risk of the ulcer becoming hard to heal.

With evidence that the number of people living with

hard-to-heal lower leg wounds is on the increase, placing more strain on healthcare resources, it is important that the NWCSP recommendations are adopted. This will ensure prompt intervention, appropriate referral, accurate assessment and effective evidence-based treatment plans that include compression therapy and wound dressings when indicated. It is hoped this will improve healing outcomes and thus quality of life.

Part of this strategy will need to consider shared care and self-management, which will require the person to gain an understanding of their wound and the prescription of effective treatments associated with positive outcomes. This includes supporting people to effectively manage some of the symptoms of VLUs, in particular the management of chronic wound fluid. If patients are managing their own wounds and can see them improving, this may empower them to take control. Hopefully, in time this will lead to a reduction in the number of hard-to-heal VLUs in the UK.

Adderley U. Covid-19 presents interesting times for those of us involved in wound care. *Nursing Times*. 2020. <https://tinyurl.com/1tk164ho> (accessed 23 February 2021)

Adderley U. Wound exudate what it is and how to manage it. *Wound Essentials*. 2008;3:8–13. <https://tinyurl.com/2n9tj8u9> (accessed 5 March 2021)

Anderson I. Understanding chronic venous hypertension. *Wound Essentials*. 2008;3:20–32 <https://tinyurl.com/v4r2jsk5> (accessed 23 February 2021)

Ashby RL, Gabe R, Ali S et al. VenUS IV (Venous leg Ulcer Study IV): compression hosiery compared with compression bandaging in the treatment of venous leg ulcers: a randomised controlled trial, mixed-treatment comparison and decision-analytic model. *Health Technol Assess*. 2014;18(57):1–293. <https://doi.org/10.3310/hta18570>

Atkin L. Venous leg ulcer prevention 2: hosiery product selection. *Nurs Times*. 2019;15:7,27-30. <https://tinyurl.com/vd2b6cdc> (accessed 23 February 2021)

Benbow M, Stevens J. Exudate, infection and patient quality of life. *Br J Nurs*. 2010; 19(Sup10):S30–6. <https://doi.org/10.12968/bjon.2010.19.Sup10.79691>

British Lymphology Society (BLS). Position paper for assessing vascular status in the presence of chronic oedema prior to the application of compression hosiery: Position Document to guide decision making. <https://tinyurl.com/z2cbrkw> (accessed 23 February 2021)

Browning P, White RJ, Rowell T. Comparative evaluation of the functional properties of superabsorbent dressings and their effect on exudate management. *J Wound Care*. 2016; 25(8):452–62. <https://doi.org/10.12968/jowc.2016.25.8.452>

Buchan J, Gershlick B, Charlesworth A, Seccombe I. Falling short: the NHS workforce. The Health Foundation, 2019. <https://tinyurl.com/7namn333>

Coleman S, Nelson EA, Vowden P et al. Development of a generic wound care assessment minimum data set. *J Tissue Viability*. 2017; 26(4):226–40. <https://doi.org/10.1016/j.jtv.2017.09.007>

Conte MS, Bradbury AW, Kolh P et al. Global vascular guidelines on the management of chronic limb-threatening ischemia. *Eur J Vasc Surg*. 2019; 69(6):35–125S.e40. <https://doi.org/10.1016/j.jvs.2019.02.016>

Dissemond J, Dowsett C, Schultz G, Serena T. EPA Made easy. *Wounds International* 2013, 4(1): <https://tinyurl.com/nutscmcn> (accessed 5 March 2021)

Dhoonmoon P, O'Neill C. How to run wound management services

- safely and effectively during Covid-19. *Nurs Pract*. 2020. <https://tinyurl.com/nvzvp8r> (accessed 23 February 2021)
- Dowsett C. Management of wound exudate. *Independent Nurse*. 2012; 2012(2). <https://doi.org/10.12968/indn.2012.6.2.89296>
- Dowsett C. Moisture in wound healing: exudate management. *Br J Community Nurs*. 2011; 16(Sup6):S6–12. <https://doi.org/10.12968/bjcn.2011.16.Sup6.S6>
- Dowsett C. Transforming venous leg ulcer management: opportunities for self-care solutions. *Wounds UK* 2021;17(1):49–55
- Edward Jones V. Microbiology and malodorous wounds. *Wounds UK*. 2018;14(4). <https://tinyurl.com/aktsz8cw> (accessed 23 February 2021)
- Gardener S. Managing high exudate wounds. *Wound Essentials*. 2012;17(1). <https://tinyurl.com/2zh928r5> (accessed 5 March 2021)
- Gethin G, Grocott P, Probst S, Clarke E. Current practice in the management of wound odour: an international survey. *Int J Nurs Stud*. 2014; 51(6):865–74. <https://doi.org/10.1016/j.ijnurstu.2013.10.013>
- Gohel MS, Heatley F, Liu X et al. A randomized trial of early endovenous ablation in venous ulceration. *N Engl J Med*. 2018; 378(22):2105–14. <https://doi.org/10.1056/NEJMoa1801214>
- Guest JF, Ayoub N, McIlwraith T et al. Health economic burden that different wound types impose on the UK's National Health Service. *Int Wound J*. 2017; 14(2):322–30. <https://doi.org/10.1111/iwj.12603>
- Guest JF, Fuller GW, Vowden P. Cohort study evaluating the burden of wounds to the UK's National Health Service in 2017/2018: update from 2012/2013. *BMJ Open*. 2020; 10(2):e045253. <https://doi.org/10.1136/bmjopen-2020-045253>
- Guest JF, Ayoub N, McIlwraith T et al. Health economic burden that wounds impose on the National Health Service in the UK. *BMJ Open*. 2015; 5(12):e009283. <https://doi.org/10.1136/bmjopen-2015-009283>
- Ham C, Charles A, Wellings D. Shared responsibility for health: the cultural change we need. *The King's Fund*, 2018. <https://tinyurl.com/hxncjn2x> (accessed 23 February 2021)
- Hofman D. Managing ulceration caused by oedema. *Wounds Essentials* 2010;5:80–86. <https://tinyurl.com/bfyfw56j> (accessed 5 March 2021)
- Hopkins A. How to apply effective multilayer compression bandage. *Wound Essentials* 2006;1:38–86. <https://tinyurl.com/yr3xnab>
- Lloyd Jones M. Exudate: friend or foe? *Br J Community Nurs*. 2014; 19(Sup6):S18–23. <https://doi.org/10.12968/bjcn.2014.19.Sup6.S18>
- Langøen A, Bianchi J. Chapter 2: Maintaining Skin Integrity. In M. Flanagan (Ed.), *Wound Healing and Skin Integrity. Principles and Practice* (pp. 18–32). 2013: John Wiley & Sons, Ltd.
- Levick JR, Michel CC. Microvascular fluid exchange and the revised Starling principle. *Cardiovascular Research*. 2010; 87(2):198–210. <https://doi.org/10.1093/cvr/cvq062>
- Lindahl E, Norberg A, Söderberg A. The meaning of living with malodorous exuding ulcers. *J Clin Nurs*. 2007; 16(3a):68–75. <https://doi.org/10.1111/j.1365-2702.2005.01550.x>
- Mortimer PS, Rockson SG. New developments in clinical aspects of lymphatic disease. *J Clin Invest*. 2014; 124(3):915–21. <https://doi.org/10.1172/JCI1608>
- NHS. Venous leg ulcer overview. 2019a. <https://tinyurl.com/44vc8srr> (accessed 23 February 2021)
- NHS. Symptoms of Sepsis 2019b. <https://www.nhs.uk/sepsis/> (accessed 23 February 2021)
- NHS England. The NHS Long Term Plan, 2019c. <https://tinyurl.com/b7fx4tz> (accessed 23 February 2021)
- NHS. Right care scenario: the variation between suboptimal and optimal pathways. Betty's story. 2017 <https://tinyurl.com/2z94b3bk> (accessed 23 February 2021)
- National Institute for Health and Care Excellence (NICE). Leg ulcer venous: differential diagnosis. 2020a. <https://tinyurl.com/yw3ttuku>
- National Institute for Health and Care Excellence (NICE). Leg ulcer infection: antimicrobial prescribing guidelines 2020b. <https://tinyurl.com/dshz5nfv> (accessed 5 March 2021)
- National Institute for Health and Care Excellence (NICE). Peripheral arterial disease: diagnosis and management. Clinical Guideline (CG147). 2020c. <https://tinyurl.com/7vfb3m5u> (accessed 5 March 2021)
- National Institute for Health and Care Excellence (NICE). Scenario: management of acute cellulitis. 2019. <https://tinyurl.com/3jtwxc2y> (accessed 5 March 2021)
- National Wound Care Strategy (NWCS). Lower limb - Recommendations for clinical care. NWCS 2020. <https://tinyurl.com/8evmzd4u> (Accessed 23 February 2021)
- Nix D. Skin and wound inspection and assessment. In: Bryant R, Nix D (eds). *Acute and Chronic Wounds: Current Management Concepts*. 5th edn. Elsevier; 2016: 109–23
- Ousey K, Stephenson J, Barrett S et al. Wound care in five English NHS Trusts: results of a survey. *Wounds UK*. 2013;9(4):20–8
- Ousey K, Roberts D. Coping with feelings associated with wound malodour. *Independent Nurse*. 2017; 3:25–26. <https://tinyurl.com/fcwyrfa3> (accessed 10 March 2021)
- Rollnick S, Miller WR, Butler CC. *Motivational interviewing in health care: helping patients change behaviour*. Guildford Press, 2008
- Romanelli M, Vowden K, Weir D. Exudate management made easy. *Wounds International* 2010;1(2). <https://tinyurl.com/m53jcs2> (accessed 23 February 2021)
- Scottish Intercollegiate Guidelines Network (SIGN). Management of chronic venous leg ulcers. *Healthcare Improvement Scotland* 2010. <https://tinyurl.com/2dbfz3z83> (accessed 23 February 2021)
- Schultz GS, Davidson JM, Kirsner RS et al. Dynamic reciprocity in the wound microenvironment. *Wound Repair Regen*. 2011; 19(2):134–48. <https://doi.org/10.1111/j.1524-475X.2011.00673.x>
- Sweeney IR, Mirafat M, Collyer G. A critical review of modern and emerging absorbent dressings used to treat exuding wounds. *Int Wound J*. 2012; 9(6):601–12. <https://doi.org/10.1111/j.1742-481X.2011.00923.x>
- Tandler S. Challenges faced by healthcare professionals in the provision of compression hosiery to enhance compliance in the prevention of venous leg ulceration. *EWMA J*. 2016;16(1):29–33. <https://tinyurl.com/yjvewway> (accessed 23 February 2021)
- Tansey EA, Montgomery LEA, Quinn JG et al. Understanding basic vein physiology and venous blood pressure through simple physical assessments. *Adv Physiol Educ*. 2019; 43(3):423–9. <https://doi.org/10.1152/advan.00182.2018>
- Vowden P, Bond E, Meuleneire F. Managing high viscosity exudate. *Wounds UK* 2015;11(1):56–60. <https://tinyurl.com/xs8nm4fy> (accessed 23 February 2021)
- Vowden P. Hard-to-heal wounds made easy. *Wounds International* 2011;4(4). <https://tinyurl.com/39n788z4> (accessed 23 February 2021)
- Waugh A Grant A. *Ross & Wilson anatomy and physiology in health and illness*. 13th edn. Elsevier; 2018
- World Union of Healing Societies (WUWHs). Consensus Document: Wound exudate, effective assessment and management. 2019. <https://tinyurl.com/yf6s6pf4> (accessed 23 February 2021)
- World Union of Wound Healing Societies (WUWHs). Compression in venous leg ulcers: a consensus document. 2008. <https://tinyurl.com/2rm6avzc> (accessed 5 March 2021)
- Wounds International. International best practice statement: optimising patient involvement in wound management. 2016. <https://tinyurl.com/t8wusbu> (accessed 23 February 2021)
- Wounds UK. Best practice statement: improving holistic assessment of chronic wounds. 2018. <https://tinyurl.com/twfz3z3b> (accessed 23 February 2021)
- Wounds UK. Best Practice Statement. Effective exudate management. 2013. <https://tinyurl.com/2jpxtmju> (accessed 23 February 2021)
- Yarwood-Ross L, Haigh C. Managing a venous leg ulcer in the 21st century, by improving self-care. *Br J Community Nurs*. 2012; 17(10):460, 462–5. <https://doi.org/10.12968/bjcn.2012.17.10.460>

# Zetuvit Plus and Zetuvit Plus Silicone superabsorbent polymer (SAP) dressings: effectiveness under compression therapy

The rest of this supplement describes the use of the Zetuvit Plus family, in combination with compression therapy, in the treatment of leg ulcers. It starts with a summary of the dressings' structure and mode of action and proceeds with four case studies describing the outcomes achieved with these superabsorbent dressings when used for this indication in clinical practice

**E**ffective wound exudate management is an important aspect of wound care. Zetuvit Plus and Zetuvit Plus Silicone are primary and secondary wound contact dressings designed to enhance exudate management (Barrett et al, 2018). These dressings fall into a category referred to as superabsorbent polymers (SAPs). They have been developed to provide extra fluid-handling capacity and are suitable for moderate to high exudate volumes in wounds of various aetiologies (Cutting and Westgate, 2012; Wiegand et al, 2015). Effective exudate handling will help reduce some of the problems affecting quality of life, such as exudate leakage and periwound maceration (Santos et al, 2017).

The SAP in the dressings quickly absorbs exudate and retains it by forming a gel. This reduces the wound bioburden, as bacteria in the exudate, along with protein-degrading enzymes and reactive oxygen species, are also trapped (Wiegand and White, 2013). This is beneficial, as elevated levels of proteinases in chronic wounds damage the wound bed and periwound skin (Chen and Rogers, 2007; Wlaschek and Scharffetter-Kochanek, 2005).

Zetuvit Plus is comprised of four layers:

- The hydrophilic wound contact layer, which allows exudate to pass into the dressing core and prevents adherence to the wound (Benbow and Stevens, 2010)
- Thin cellulose diffusion layer, which allows exudate to be quickly transferred into the absorbent core
- A combination of soft cellulose fluff blended with a SAP that quickly absorbs and retains exudate (Gray, 2010)
- Hydrophobic outer layer that is water repellent and air permeable.

Zetuvit Plus Silicone has an additional soft silicone contact layer, supporting atraumatic dressing removal (Atkin et al, 2020).

This combination provides highly effective exudate management, with excellent prevention of leakage and strikethrough, as well as longer wear times. The combination of cellulose fluff and SAP provides high levels of comfort and padding for patients, promoting ease of removal.

Zetuvit Plus and Zetuvit Plus Silicone can be used effectively under compression therapy, making them a suitable choice for use in leg ulcer management.

- Atkin L, Barrett S, Chadwick P et al. Evaluation of a superabsorbent wound dressing, patient and clinician perspective: a case series. *J Wound Care*. 2020;29(3):174–82. <https://doi.org/10.12968/jowc.2020.29.3.174>
- Benbow M, Stevens J. Exudate, infection and patient quality of life. *Br J Nurs* 2010;19(20): S30–6. <https://doi.org/10.12968/bjon.2010.19.Sup10.79691>
- Barrett S, Callaghan R, Chadwick P et al. An observational study of a superabsorbent polymer dressing evaluated by clinicians and patients. *J Wound Care*. 2018; 27(2):91–100. <https://doi.org/10.12968/jowc.2018.27.2.91>
- Chen WY, Rogers AA. Recent insights into the causes of chronic leg ulceration in venous diseases and implications on other types of chronic wounds. *Wound Repair Regen*. 2007;15(4):434–449. <https://doi.org/10.1111/j.1524-475X.2007.00250.x>
- Cutting KF, Westgate SJ. Super-absorbent dressings: how do they perform in vitro? *Br J Nurs*. 2012; 21(20):14–9. <https://doi.org/doi/10.12968/bjon.2012.21.Sup20.S14>
- Gray D. Meeting the clinical challenges posed by highly exuding wounds. Internal publication. Data on file. SMTL report 4816,2015. 2010. <https://tinyurl.com/2db9546u> (accessed 9 March 2021)
- Santos VL, Oliveira AS, Amaral AF et al. Quality of life in patients with chronic wounds: magnitude of changes and predictive factors. *Rev Esc Enferm USP*. 2017;51(0):e03250. <https://doi.org/10.1590/s1980-220x2016049603250>
- Wiegand C, Tittelbach J, Hipler UC, Elsner P. Clinical efficacy of dressings for treatment of heavily exuding chronic wounds. *Chronic Wound Care Manage Res*. 2015;2:101–111.
- Wiegand C, White RJ. Binding and inhibition of protease enzymes, including MMPs, by a superabsorbent dressing in vitro. *J Wound Care* 2013; 22(5):221–229. <https://tinyurl.com/mw-wea7vn> (accessed 9 March 2021)
- Wlaschek M, Scharffetter-Kochanek K. Oxidative stress in chronic venous leg ulcers. *Wound Repair Regen*. 2005;13(5):452–461. <https://doi.org/10.1111/j.1067-1927.2005.00065.x>

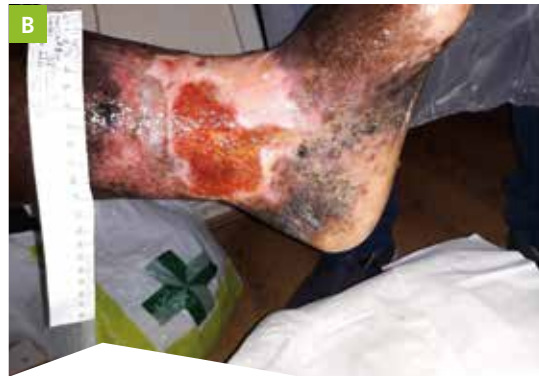
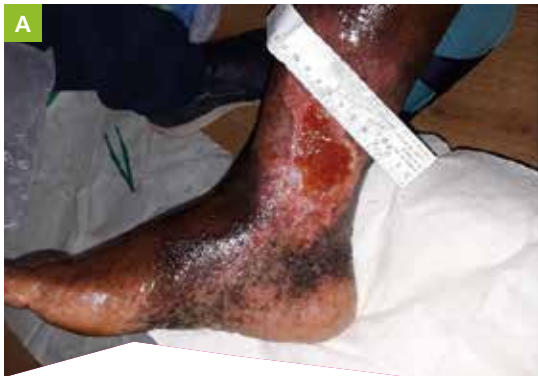
Figure 1. Case study 1: the wounds before the start of treatment with the superabsorbent dressing and compression therapy: the ulcers are on the medial aspect of the right (a) and left legs (b)

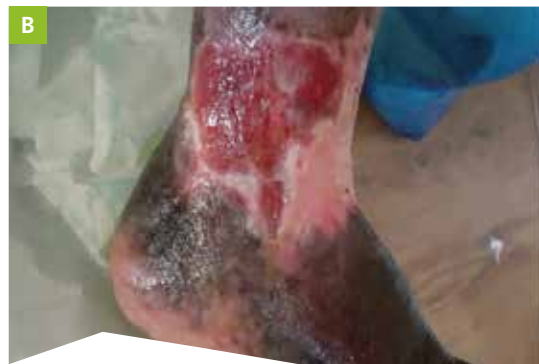
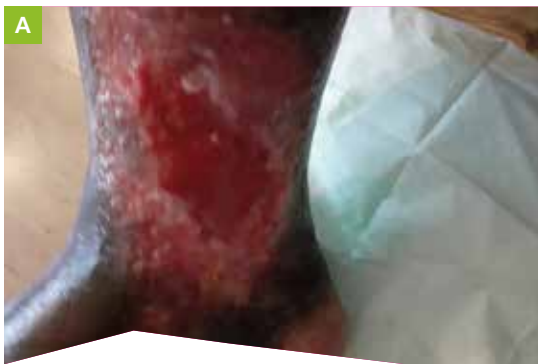
Figure 2 Case study 1. the wounds after 4 weeks of treatment: right (a) and left legs (b)

## Case study 1

Anne, a 64-year-old woman with a 4-year history of leg ulceration, was referred by her GP to the tissue viability service for advice about recurrent bilateral leg ulcers that were deteriorating. She had a medical history of normocytic anaemia, overactive bladder, osteoarthritis, mucous membrane pemphigoid (a rare chronic autoimmune disorder characterised by blistering in the mucous membranes, such as the mouth), lumbar disc degeneration, intraductal carcinoma *in situ* followed by a total mastectomy, blepharoplasty (cosmetic procedure for the eyelids), diabetes mellitus type 2, obesity and essential hypertension. She had an (unspecified) foot deformity, which was being cared for by podiatry.

Before the referral, Anne's leg ulcers had been managed by district nurses (DNs) with a two-layer compression bandaging system. The DN's visited Anne at home twice weekly. In addition, she was prescribed paracetamol and codeine to relieve her ulcer-

associated pain. She was not taking any over-the-counter medication or using illicit drugs.

At presentation, the tissue viability nurse (TVN) performed a holistic assessment that included use of Doppler ultrasound. The ankle brachial pressure indices (ABPIs) were 1.07 for her right leg and 1.10 for her left leg. Anne's legs and feet were warm to the touch, with skin colour changes within the gaiter region and localised oedema. She had hyperkeratosis on both the lateral and medial aspects of her feet. The ulcer on her left leg measured 8 x 7 cm and the one on her right leg 6 x 4.5 cm; both were covered with 90% granulation tissue and 10% slough and were producing a large volume of malodorous, purulent exudate (Figure 1). The periwound skin was red and inflamed. A swab was taken for culture and sensitivity, following which a course of oral antibiotics (flucloxacillin) was prescribed.

Holistic assessment undertaken by TVN revealed that Anne had a complex medical history. She was non-



concordant in that she had not taken her analgesia as prescribed, applied to her wounds a bacitracin zinc ointment recommended and purchased by her daughter, who is a nurse in the US, and sometimes removed her compression bandages between DN visits, saying her legs were painful. The holistic assessment also revealed that, to help maintain some level of independence, Anne would wash her legs in a bowl with a paraffin-based emollient before the DN visits.

At the assessment, Anne's self-reported pain score was 9/10 (where 1 is no pain and 10 is unbearable). Many factors could have caused the ulceration, or at the very least now be contributing to their non-healing: the non-concordance described above, osteoarthritis, exacerbation of her pemphigoid, venous disease and severe pain. In some people with mucus membrane pemphigoid, blisters form on other areas of the body, including skin on the limbs (Peraza, 2020).

The deterioration and pain in her leg ulcers was such that Anne's mobility was reduced, limiting her ability to socialise, and she sometimes found it difficult to walk.

The TVN moisturised both legs with the same emollient that Anne had used previously and, at her insistence, applied the bacitracin zinc ointment. Zetuvit plus silicone superabsorbent (pad size 25 x 20cm) was applied as a secondary dressing for exudate management. The TVN selected the dressing because of its size, ease of application and removal, conformability and ability to protect the periwound skin, based on her previous clinical experience. The same two-layer compression therapy bandage continued to be applied. Anne was initially reluctant to try the superabsorbent, believing that no wound dressing could help promote healing, and only consented after receiving written information about it and its indications.

The superabsorbent dressing conformed well to Anne's foot, despite the deformity, and could be applied under the compression bandage without difficulty. The DN continued to make twice weekly visits for dressing changes. Unfortunately, Anne remained non-concordant for the entire period covered by this case study, even though both the DNs and TVN had tried to help her address the reasons for this and explained the benefits of compression therapy. This made the leg ulcer management extremely challenging. Anne also continued to self-manage her pain, taking her pain medication only when she thought it necessary.

Anne was reassessed by the TVN 4 weeks later. The assessment showed that the limb function had been preserved during this time. In addition, the exudate volume had decreased, the wounds had reduced

in size, with the one on the left leg now measuring 7 x 6 cm and the one on the right leg 5 x 4.5 cm (Figure 2). The wound bed was now fully covered with healthy granulation tissue. There were no clinical signs of infection and the oedema had reduced.

Peraza DM. Mucous membrane pemphigoid. MSD Manual, 2020. <https://tinyurl.com/3xs79adw> (accessed 11 March 2021)

**Delma Duffus-Grovel, Tissue Viability Nurse Specialist, Community Team, Guy's and St Thomas's Hospital NHS Foundation Trust, London**

## Case study 2

A 77-year-old man with a heavily exuding leg ulcer of 4 weeks' duration was referred by his GP to a wound advisory clinic. The patient, who has a history of venous and mixed-aetiology leg ulceration, presented with a recurrent leg ulcer, of 6 weeks' duration, that was extending beyond its original size. His medical history included heart failure, myocardial ischaemia, contact dermatitis, hypercholesterolaemia, duodenal ulceration and prostate cancer. At the time of assessment, he was taking codeine and paracetamol for pain relief. He had no known allergies.

Prior to the referral, the leg ulcer had been managed by district nurses (DNs) with a 100% manuka honey dressing and a carboxymethyl cellulose (CMC) gelling fibre dressing. They found the wound challenging, and

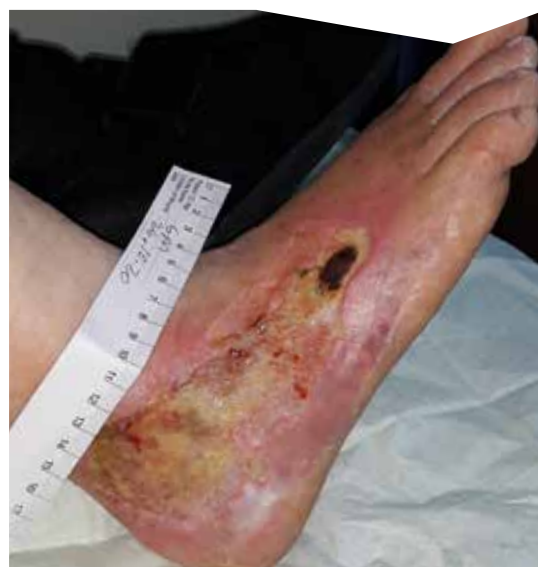
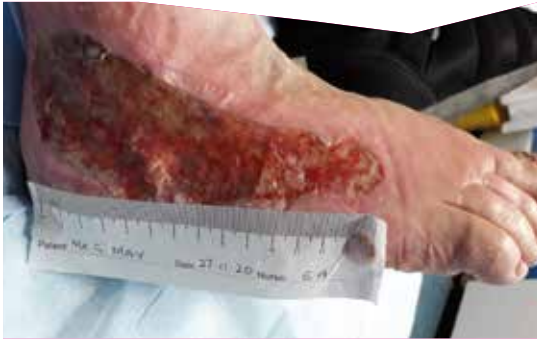
Figure 3. Case study 2: the wound before the start of treatment with the superabsorbent dressing and compression therapy



**Figure 4.** Case study 2: the wound after 4 weeks of treatment with the superabsorbent dressing and compression therapy

their rationale for this regimen was to treat a suspected wound infection.

Following the patient's presentation at the clinic, the tissue viability nurse (TVN) performed a holistic assessment that included use of Doppler ultrasound. The ankle brachial pressure indices (ABPIs) were 0.76 for the right leg and 0.73 for the left leg, indicating this was a mixed-aetiology leg ulcer that would require reduced compression therapy as well as referral for further vascular assessment, which was arranged. There was localised oedema below the ankle, with some ankle flare. Both feet and legs were warm to the touch.

The leg ulcer, which measured 16 x 5 cm, was located on the lateral aspect of the malleoli and dorsum of the foot. The wound bed was principally covered with adherent slough and some necrosis (Figure 3). The wound was producing a large volume of purulent exudate, was malodorous and extremely painful, particularly to the touch. The patient said the wound pain was intense at times (with a self-reported pain score of 9 out of 10, where 10 is unbearable), and that it was generally worst at night. The periwound skin was inflamed, but still intact, albeit fragile.

A microbiology swab was taken for culture and sensitivity, and the patient was prescribed a course of oral flucloxacillin antibiotics.

The patient had a complex medical history and many factors—his arterial disease, venous disease and the severe pain—could have caused this ulcer, or at the very least be contributing to its non-healing.

The TVN moisturised the leg with a paraffin-based ointment. To reduce the bacterial colonisation, she applied silver sulfadiazine cream to the wound and then a zinc paste and ichthammol bandage, as this is specifically indicated for eczema and dermatitis.

Although this product combination is not often used in clinical practice, on this occasion it was effective in reducing the bacterial overload and facilitating wound bed preparation. A superabsorbent dressing (Zetuvit Plus Silicone superabsorbent pad 25 x 20 cm) was applied as a secondary dressing. This was selected because of its ability to retain exudate, manage malodour and for its ease of use and conformability, based on the TVN's previous clinical experience.

A two-layer inelastic compression bandaging system was also applied. Research has suggested that compression with short-stretch inelastic bandages may be used safely and effectively in this group of patients where accurate assessment has been conducted and care supervised by a specialist practitioner (Knowles et al, 2013). Within our organisation's leg ulcer pathway, the ABPI must be between 0.70 and 0.79 before reduced compression can be applied and between 0.8 and 1.3 before full compression can be used (Wounds UK, 2016). This meant the patient could be offered reduced compression therapy. The patient reported that he found this bandaging system comfortable, having used it in the past.

The wound was managed by the DNs, under the careful supervision of the TVN. The DNs visited the patient three times each week, when they assessed him and his ulcer and changed the dressings. The ulcer improved during this period, with a gradual reduction in pain scores and clinical signs of infection. The silver sulfadiazine cream was discontinued after 2 weeks.

After 4 weeks, the patient was assessed by the TVN at the clinic. The wound now measured 14 x 4.5 cm. The exudate volume had decreased to moderate, the wound bed was fully covered with granulation tissue (Figure 4). The patient's self-reported pain score had reduced to 4 /10; he was taking co-codamol to manage this pain. The dressing has successfully retained the exudate, and there was a significant improvement in the condition of the periwound skin.

The patient's quality of life has improved as he was able to mobilise better and gained more independence. He also felt more confident when going out, as there was no accidental leakage of exudate from his ulcer.

Knowles A, Charles H, Coulborn A, Hampton S. Evaluation of a new two component inelastic compression bandage kit. *J Comm Nurs.* 2013; 27(3):10–13

Wound UK. Best Practice Statement. Holistic Management of venous leg ulceration. 2016. <https://tinyurl.com/znfysukp> (accessed 24 March 2021)

**Delma Duffus-Grovel, Tissue Viability Nurse Specialist, Community Team, Guy's and St Thomas's Hospital NHS Foundation Trust, London**

## Case study 3

A 76-year-old woman presented with bilateral venous leg ulcers complicated by the presence of calcium deposits in the wound beds. This case study focuses on the management of the left leg, which had a highly exuding, malodorous ulcer.

The patient's past medical history included hypertension, epilepsy, macular degeneration, varicose vein removal in the right leg in 2002 and endovenous laser ablation of her left leg in 2020.

The current ulcers had been present for 8 months and had a history of recurrence over the previous 5 years. A variety of absorbent and antimicrobial dressings, compression therapy and a skin-care regimen had been used over the preceding 8 months, with little improvement in the wound or periwound skin.

The patient presented with multiple small, scattered ulcers on the medial and lateral area of the lower limb, ranging from 2 x 1 cm to 1 x 1 cm in size (Figure 5). Her ankle brachial pressure index (ABPI) was 1.10, with easily palpable foot pulses. The wounds were producing a high volume of exudate, causing maceration to the periwound skin, despite dressing

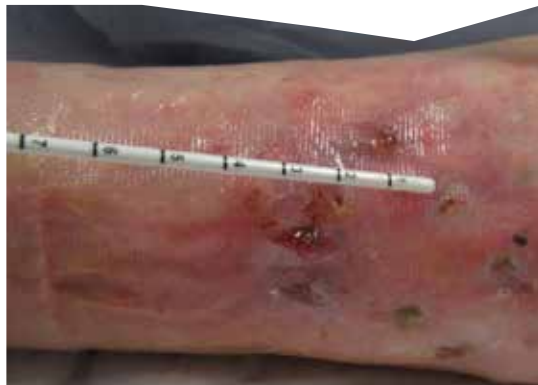

Figure 5. Case 3: the wounds at presentation

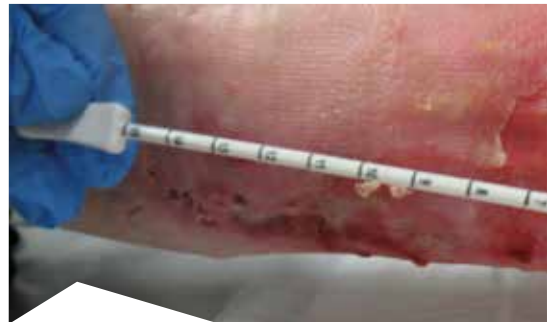
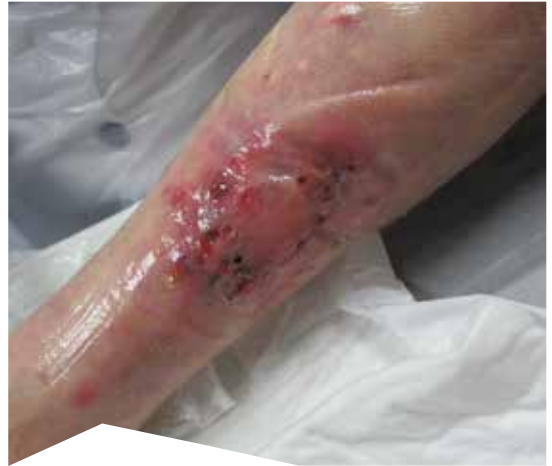
Figure 6. Case 3: the wounds after 2 weeks of treatment

changes three times a week. The wound beds were covered with 50% slough and buds of granulation tissue (20%). The remaining 30% of the wound bed consisted of calcium deposits. The patient's serum calcium and phosphate levels were normal.

The patient reported that the ulcers were painful, particularly at dressing change (her self-reported pain score at dressing change was 4/10, where 10 is the worst pain possible). She said she was embarrassed about the malodour and strikethrough of exudate onto her compression bandages and so tended to socially isolate. The exudate volume was such that her footwear also often became soaked.

At the presentation, the tissue viability nurse (TVN) specialist encouraged her to voice her concerns and reassured her that they would continue to try to find a dressing to better manage the exudate and malodour. The TVN also included the patient's daughter in the care planning with the patient's consent.

A primary dressing that binds to and sequesters bacteria was used to manage a suspected bacterial

load; Zetuvit Plus 10 x 20 cm non-adhesive dressing was applied as a secondary dressing in an attempt to manage the exudate more effectively. The non-adhesive version of the dressing was chosen as the periwound skin was very fragile (paper thin) and macerated from the exudate. A skin-care regimen was implemented using emollients and barrier creams to protect the fragile periwound skin. An inelastic two-layer full compression bandage system providing 35–40 mmHg was applied over the primary and secondary dressings. Dressings were changed three times weekly with a plan to adjust frequency in response to the exudate level. Short-acting opioid analgesia was prescribed to manage the pain at dressing change.

After 2 weeks, the wound beds consisted of 50% slough and 50% granulation tissue (*Figure 6*). Loose calcium deposits were removed before cleansing the wound with an antimicrobial solution. The wound sizes were unchanged from the previous assessment. Although the exudate volume remained high, it was not striking through onto the outer compression dressing and the patient was happy with this outcome. The skin remained macerated and very fragile, and so continued to be treated with emollient washes and a moisturising barrier cream. To optimise the skin care, the same dressing regimen was continued. Her pain score at dressing change was now 2/10. Consideration was given to changing the primary dressing in view of the condition of the periwound skin, but the patient found the bacteria-binding primary dressing the most comfortable of the multiple dressing types she had tried in the 8 months of the ulcer's duration.

After 3 weeks, the amount of granulation tissue present had increased to 90%, and there was only 10% slough, although there were persistent calcium deposits. The wound dimensions were unchanged. The periwound skin was still fragile and macerated. The exudate volume remained high but again there was no strikethrough onto the outer bandages. The patient reported feeling more comfortable and confident with the dressings due to the lack of strikethrough (*Figure 7*).

By week 4, the wound beds measured 2.5 x 0.5 cm and 1.5 x 0.5 cm. Further calcium deposits were removed from the wound beds. However, the volume of exudate had increased, resulting in strikethrough onto the compression bandage and a deterioration in the condition of the periwound skin. The patient reported an increased pain score of 6/10 and complained of pain between dressing changes. There were signs of local infection, with increased slough and moisture on the wound bed. The public health

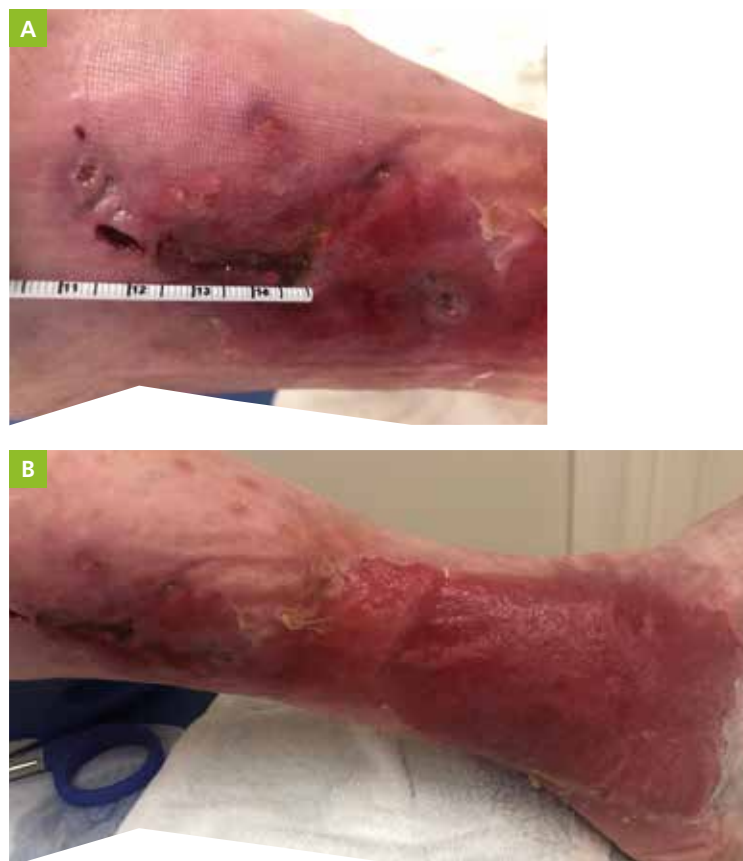

Figure 7. Case study 3: the wounds after 3.5 weeks of treatment

nurse reported that the patient was removing the compression bandages between dressing changes as she found them uncomfortable. A wound swab was taken for culture and sensitivity, and the result showed the presence of *Pseudomonas*, *Enterococcus* and diphtheroids. Blood results demonstrated that the white blood cell count and inflammatory marker values were normal.

Use of an antimicrobial cleansing solution was initiated. The bacterial-binding dressing was replaced with a silver antimicrobial dressing and the Zetuvit Plus with an alternative superabsorbent. The same skin-care regimen and four-layer compression bandaging system continued to be applied, with the dressing change frequency continuing at three times weekly. The patient was advised to take her prescribed analgesia regularly to manage pain more effectively. However, the patient subsequently required a short inpatient stay with intravenous antibiotics, daily dressing changes, skin



care and leg elevation to optimise her care.

During the 3 weeks in which Zetuvit Plus was used, it continued to be changed three times a week, but was reported by the health professionals to have a good absorbency, containing the exudate with no strikethrough. The patient found this reassuring, as she was not worried that exudate would leak through the dressings. She also reported that the dressing felt comfortable under the compression bandage.

Unfortunately, the exudate volume increased after week 4 in response to a suspected local wound infection and the periwound skin became very macerated. Other factors that may have influenced this outcome include patient choice in relation to the degree of compression tolerated. The level of compression tolerated at a given dressing change could vary, depending on the patient's level of discomfort.

Nevertheless, this case study illustrates the use of Zetuvit Plus in the management of a challenging venous leg ulcer complicated by the presence of calcium deposits, a high exudate volume, fragile periwound skin, as well as the presence of bacterial load and a subsequent wound infection that warranted hospital admission.

**Helen Meagher, Registered Advanced Nurse Practitioner Tissue Viability, and Shauna Chaplin, Vascular Clinical Nurse Specialist, both at University Hospital Limerick, Republic of Ireland**

## Case study 4

**A** 68-year-old woman with multiple sclerosis (MS) and lower limb lymphoedema developed a leg ulcer. She normally wore below-knee compression garments to prevent build up of lymph fluid, 'wet' legs and further ulceration. However, due to a period of immobility exacerbated by her MS, her lower limbs had become larger than usual and she was unable to wear her hosiery. The patient had had leg ulcers in the past and usually self-managed her wounds with minimal input from health professionals.

The patient had been managing this ulcer and the periwound skin herself with a zinc-based bandage and absorbent pads that she had purchased online. Unfortunately, these needed changing up to four times daily. As the wound did not improve, she contacted her GP, who prescribed a 7-day course of oral antibiotics. The GP also contacted a local district nurse, who visited the patient at her home the next day to assess the wound and limb.

On assessment, the leg was found to be red and

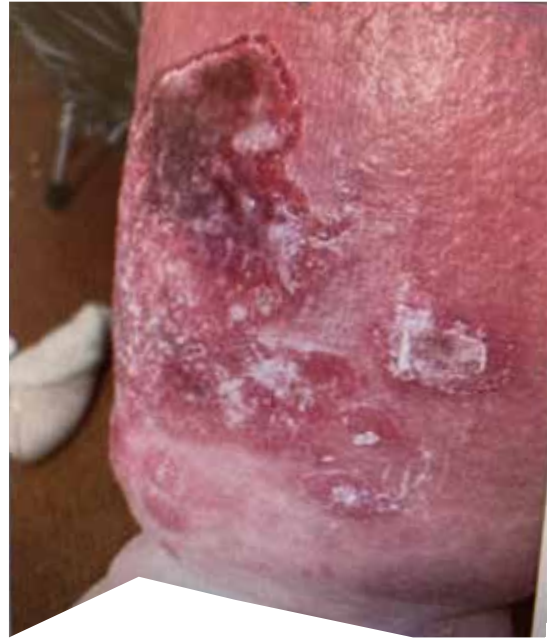

Figure 8. Case 4: the wound at week 1

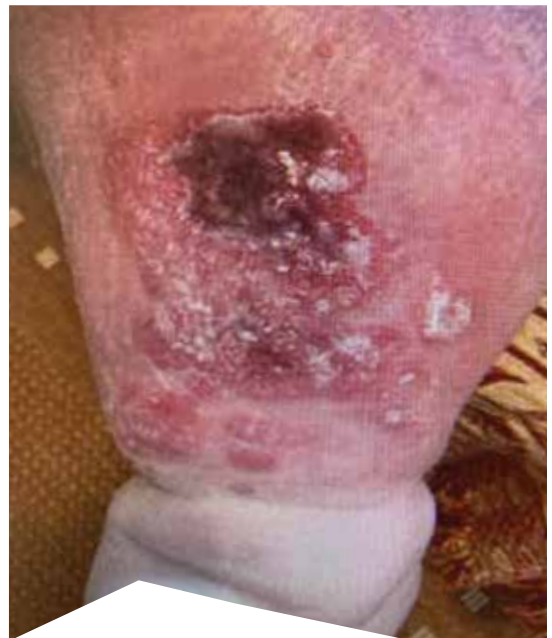

Figure 9. Case 4: the wound at the end of week 2

hot, most likely because of the poorly managed lymphoedema in the lower limb. It was decided that compression therapy would be beneficial at this stage. The limb was so large due to the lymphoedema that the nurse was unable to perform Doppler ultrasound assessment to calculate the ankle brachial pressure



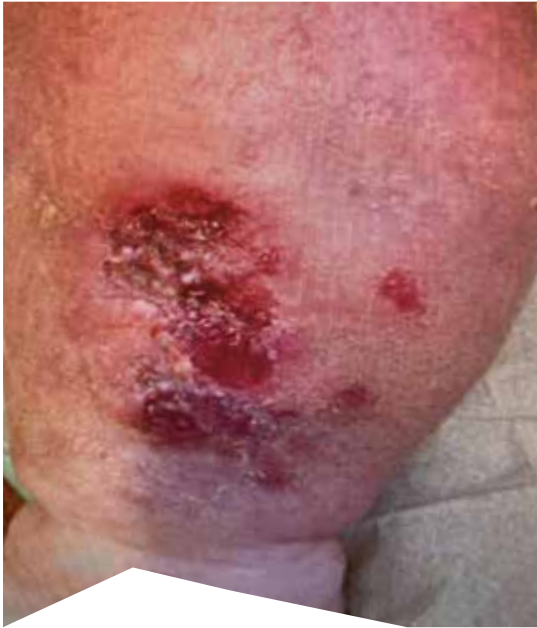

Figure 10. Case 4: the wound at week 4

index. However, a full holistic assessment was undertaken in which any arterial characteristics were ruled out. In addition, in a previous assessment, the lymphoedema services had deemed the patient suitable for compression therapy.

The ulcer measured 3 x 3 cm and was fully covered with slough (Figure 8). It was producing a high volume of exudate. The periwound skin was macerated, red and hot to the touch, and there was extensive excoriation on the left shin. The patient's vital signs were within the normal range.

A plan of care was discussed with the patient and jointly agreed. The treatment regimen was as follows:

- An ichthammol-based bandage, to be applied over the ulcerated and excoriated areas, which the patient would change every 3 to 4 days. This primary layer dressing was chosen on the basis of the author's previous clinical experiences of its soothing properties, as reported by patients, and her observations of its ability to gently debride and reduce skin inflammation
- A superabsorbent dressing (Zetuvit Plus) to retain the exudate and prevent further excoriation to the periwound skin. This would be changed when needed
- Use of an adjustable wrap-style compression system to reduce the lymphoedema.

At the end of week 2, the ulcer measured

1.5 cm x 2 cm wide (length x width). It was still fully covered with slough (Figure 9) but the exudate volume had reduced from high to moderate. The superabsorbent dressing, which had initially needed to be changed twice daily, now required changing once daily. Maceration was still evident on the periwound skin, but there was less excoriation. The patient reported that the wrap compression system felt more comfortable and easier to handle than the compression hosiery she had previously used. The lower limb circumference at the calf had reduced by 3 cm.

By the end of week 4, the ulcer measured 1.3 x 1.5 cm, but was still fully covered with slough (Figure 10). The exudate volume was now low to moderate and there was less excoriation on the periwound skin. The superabsorbent dressing needed changing every 2 to 3 days. The limb had regained its usual shape with the wrap compression system, which the patient decided to keep on using in place of her previous hosiery.

The combined use of the wrap compression system and the Zetuvit Plus superabsorbent pad allowed this patient to become socially active again. Having a very wet wound had been socially debilitating; she had been constantly worried about the dressings leaking, her shoes and trousers becoming wet, malodour and the stigma associated with wet legs. Use of the superabsorbent dressing not only helped the patient regain her confidence, but it also reduced the costs associated with the nurse's input and multiple dressing changes.

**Sian Davies, District Nurse with Specialist Interest in Chronic and Complex Wounds, 3Ts Locality, Carmarthenshire**

All patient names have been changed. All patients gave informed consent



**MA HEALTHCARE**

A MARK ALLEN GROUP COMPANY